

# Technical Considerations for Filler and Neuromodulator Refinements

José Raúl Montes, MD, FACS, FACCS\*; Anthony J. Wilson, MD†; Brian L. Chang, MD†; Ivona Percec, MD, PhD†

**Background:** The toolbox for cosmetic practitioners is growing at an unprecedented rate. There are novel products every year and expanding off-label indications for neurotoxin and soft-tissue filler applications. Consequently, aesthetic physicians are increasingly challenged by the task of selecting the most appropriate products and techniques to achieve optimal patient outcomes.

**Methods:** We employed a PubMed literature search of facial injectables from the past 10 years (2005–2015), with emphasis on those articles embracing evidence-based medicine. We evaluated the scientific background of every product and the physicochemical properties that make each one ideal for specific indications. The 2 senior authors provide commentary regarding their clinical experience with specific technical refinements of neuromodulators and soft-tissue fillers.

**Results:** Neurotoxins and fillers are characterized by unique physical characteristics that distinguish each product. This results in subtle but important differences in their clinical applications. Specific indications and recommendations for the use of the various neurotoxins and soft-tissue fillers are reviewed. The discussion highlights refinements in combination treatments and product physical modifications, according to specific treatment zones.

**Conclusions:** The field of facial aesthetics has evolved dramatically, mostly secondary to our increased understanding of 3-dimensional structural volume restoration. Our work reviews Food and Drug Administration–approved injectables. In addition, we describe how to modify products to fulfill specific indications such as treatment of the mid face, décolletage, hands, and periorbital regions. Although we cannot directly evaluate the duration or exact physical properties of blended products, we argue that “product customization” is safe and provides natural results with excellent patient outcomes. (*Plast Reconstr Surg Glob Open* 2016;4:e1178; doi: 10.1097/GOX.0000000000001178; Published online 14 December 2016.)

The injectable armamentarium for cosmetic practitioners is growing at an unprecedented rate. There is continual development of novel products and expanding off-label indications for neuromodulators and fillers. Consequently, reconstructive and aesthetic physicians are increasingly challenged by the task of selecting the most appropriate products and injection techniques to achieve the best overall outcome. Optimal patient outcomes must be consistent with the patient’s specific anatomy, treatment goals, lifestyle, budget, and psychological context, among others. The authors believe that the greatest challenge of every cosmetic practitioner is to determine

precisely where and what to inject, taking into consideration the many different and unique facial features and ethnicities in a globalized market. Here, we review Food and Drug Administration (FDA)-approved injectables and describe how product modification—e.g., blending with anesthetic agents or other diluents—can result in a better

From the \*Department of Ophthalmology, Medical Science Campus, University of Puerto Rico, San Juan, Puerto Rico; and †Division of Plastic Surgery, Perelman School of Medicine, University of Pennsylvania, Philadelphia, Pa.

Presented at the The Cosmetic Bootcamp meeting, Aspen, Colo., July 8–11, 2016.

Received for publication May 20, 2016; accepted October 24, 2016. Copyright © 2016 The Authors. Published by Wolters Kluwer Health, Inc. on behalf of The American Society of Plastic Surgeons. All rights reserved. This is an open-access article distributed under the terms of the Creative Commons Attribution-Non Commercial-No Derivatives License 4.0 (CCBY-NC-ND), where it is permissible to download and share the work provided it is properly cited. The work cannot be changed in any way or used commercially without permission from the journal.

DOI: 10.1097/GOX.0000000000001178

**Disclosure:** José Raúl Montes has served as a consultant, speaker, and trainer for Allergan, Galderma, Merz, and Valeant. Ivona Percec has served as a consultant for Galderma. Neither of the other authors has any financial disclosures. The Article Processing Charge for this proceeding was paid for by Allergan plc, as part of an unrestricted educational grant to support the entire Cosmetic Boot Camp 2016 Supplement. Allergan plc had no involvement in the production, selection, or review of this proceeding supplement.

Supplemental digital content is available for this article. Clickable URL citations appear in the text.

**Cosmetic Bootcamp:** PRS Global Open proudly publishes the proceedings from The Cosmetic Bootcamp July 2016 meeting that was held in the St Regis Resort in Aspen, Colorado on July 8–11, 2016.

option for delicate or complex anatomic areas. The techniques described should permit experienced injectors to artfully and safely design customized injectable regimens for patients.

## NEUROMODULATORS

### Scientific Background

Aesthetic neuromodulation with botulinum toxin type A is the most commonly performed cosmetic procedure in the United States, with 6.7 million injections performed in 2014.<sup>1</sup> Currently, there are 3 FDA-approved botulinum toxin type A formulations: onabotulinumtoxinA (*Botox*; Allergan), abobotulinumtoxinA (*Dysport*; Galderma), and incobotulinumtoxinA (*Xeomin*; Merz Pharmaceuticals). All 3 are derived from the *Clostridium botulinum* toxin and act at the neuromuscular junction to paralyze muscles by cleaving synaptosomal-associated protein 25 that facilitates acetylcholine vesicular release.<sup>2</sup> Although all 3 toxins cause muscle paralysis, they differ in their preparation, mechanism of action, storage, dilution, and dosing<sup>3-5</sup> (Table 1). Despite these distinctions and anecdotal observations that these products are not interchangeable, clinical studies remain inadequate and have failed to demonstrate consistent substantive differences between neurotoxins.<sup>6-22</sup> Limited data suggest that incobotulinumtoxinA has a more rapid onset and longer duration,<sup>10</sup> whereas abobotulinumtoxinA has greater spread,<sup>11</sup> and onabotulinumtoxinA has greater strain reduction.<sup>12</sup> Importantly, all neurotoxins elicit similar positive effects on patients' self-perception of appearance.<sup>13</sup> The authors consider that the 3 neurotoxins do behave slightly differently in the clinical setting and that strategically tailored dilutions of a given product may be superior in specific anatomic sites and in specific patients.

### Refinements in Clinical Neuromodulator Application

#### Upper Face

Techniques of neuromodulation of the upper face, consisting of the frontalis, corrugator, procerus, orbicularis oculi, and nasalis muscles, have rapidly evolved. The optimal treatment of the upper face is presented in Figure 1 and Table 2. The ideal patient is one without

static rhytids, brow or eyelid ptosis, and severe volume atrophy of the upper face. Patients must be educated about the need to treat the entire anatomic region synergistically to avoid unnatural effects. Treatment goals should be to undercorrect and allow subtle motion and expression. The selection of a particular neuromodulator should be based upon the injector's experience and the patient's anatomy.

#### Perioral Area

Neuromodulation of the perioral region presents a unique anatomic challenge. The goal of neuromodulation in this region is to both prevent and soften perioral rhytids. In addition, physicians seek to improve the shape and motion of the perioral complex while preserving smiling, mastication, and articulation. Given this fine balance, neuromodulation of the perioral region should be undertaken by experienced injectors after extended discussions with patients about expected changes in perioral motion. The ideal patient demonstrates either early dynamic vertical rhytids, depression of the oral commissures secondary to overactive depressor anguli oris activity, or a "gummy smile" secondary to hyperactivity of the "Yonsei point," at the intersection of the 3 lip levators. Lip sphincter, elevator, and depressor balance must be meticulously characterized in relation to underlying bony structure, dentition, and occlusion before treatment. None of the currently available neurotoxins are FDA approved for perioral injection.

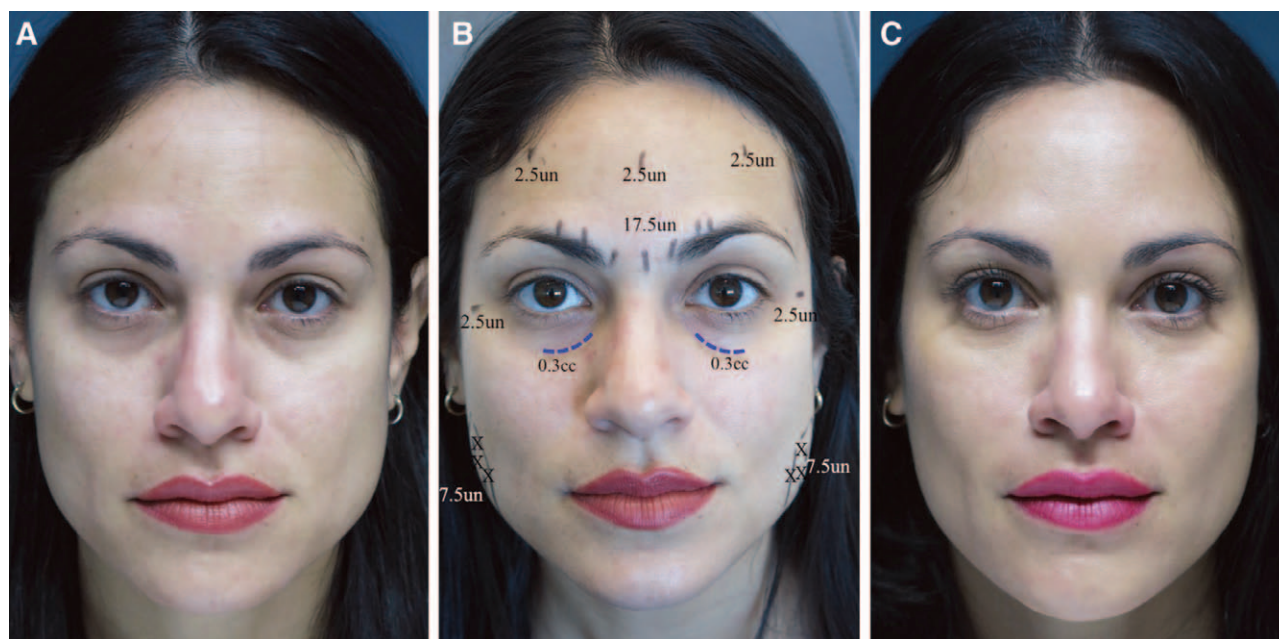
Neuromodulation of the perioral region requires a precise understanding of perioral anatomy. In this region, the authors prefer neurotoxins prepared with high dilution volumes using the lowest possible dosing as given in Table 3. (See figure, Supplemental Digital Content 1, which shows the optimal treatment of neurotoxin: pattern of injection, <http://links.lww.com/PRSGO/A333>.)

#### Jawline and Neck

Neuromodulation of the jawline and neck can significantly improve the shape and motion of the lower facial region. The authors have developed the following principles in the treatment of this area: (1) A higher reconstitution volume of 4 mL with onabotulinumtoxinA

**Table 1. Neurotoxin Preparation, Mechanism of Action, Storage, Dilution, and Dosing**

	<b>Botox Cosmetic, OnabotulinumtoxinA</b>	<b>Dysport, AbobotulinumtoxinA</b>	<b>Xeomin, IncobotulinumtoxinA</b>
Manufacturer	Allergan, Inc.	Galderma Pharma S.A.	Merz Pharmaceuticals GmbH
FDA approval	2002	2009	2011
Composition	C botulinum toxin type A, ATCC 3502 (Hall strain), hemagglutinin complex, 0.5 mg human serum albumin, 0.9 mg NaCl	C botulinum toxin type A, ATCC 3502 (Hall strain), hemagglutinin complex, 0.125 mg human serum albumin, 2.5 mg lactulose	C botulinum toxin type A, ATCC 3502 (Hall strain), 1.0 mg human serum albumin, 4.7 mg sucrose
Toxin per 100 units	0.73 ng	0.65 ng	0.44 ng
Storage	36°F–46°F°	36°F–46°F	68°F–77°F
Dilution preservative-free NaCl	2.5 mL	2.5 or 1.5 mL	Variable
Onset of treatment effect <sup>6</sup>	Female: 5.29 d; male: 5.89 d	Female: 5.32 d; male: 5.93 d	Female: 3.02 d; male: 3.36 d
Duration of treatment effect <sup>6</sup>	Female: 140.65 d; male: 116.61 d	Female: 139.69 d; male: 115.81 d	Female: 146.12 d; male: 121.14 d
Spread <sup>7</sup>	373.9 mm <sup>2</sup>	460.2 mm <sup>2</sup>	325.0 mm <sup>2</sup>
Strain reduction <sup>8</sup>	66.1%	51.4%	42.8%
Patient satisfaction <sup>9</sup>	28.9%	18.3%	35.7%



**Fig. 1.** Patient to “fill”: a young patient, 33 years old with little to no fat shown and clear demarcation line. Restylane-L 0.5 mL blended with 0.2 mL lidocaine 1%; 0.3 mL was injected on each side with a 27-G × 1 in. cannula. A, Before, (B) marks, (C) tear trough injection with blended Restylane-L and Botox upper face and masseteric muscles.

**Table 2. Upper Face Neurotoxin Injections**

Neurotoxin	Corrugators and Procerus		Frontalis (Microinjections 1–2 Units)		Orbicularis Oculi (Microinjections 1–2 Units)		Nasalis	
	Units	Dilution (mL)	Units	Dilution (mL)	Units	Dilution (mL)	Units	Dilution (mL)
IncobotulinumtoxinA*	10–30	2.5	5–20	4	10–30	4	5–10	2.5
OnabotulinumtoxinA†	10–30	2.5	5–20	4	10–30	4	5–10	2.5
AbobotulinumtoxinA‡	30–90	2.5	15–60	4	30–90	4	5–10	2.5

\*Xeomin, 100 unit vial.  
 †Botox, 100 unit vial.  
 ‡Dysport, 300 unit vial.

**Table 3. Perioral Area Neurotoxin Injections**

Neurotoxin	Orbicularis Oris		Yonsei Point		Depressor Anguli Oris		Mentalis	
	Units	Dilution (mL)	Units	Dilution (mL)	Units	Dilution (mL)	Units	Dilution (mL)
IncobotulinumtoxinA	2–3	4	1–4	2.5	3–5	2.5	3–5	2.5
OnabotulinumtoxinA	2–3	4	1–4	2.5	3–5	2.5	3–5	2.5
AbobotulinumtoxinA	6–9	4	3–12	2.5	9–15	2.5	9–15	2.5

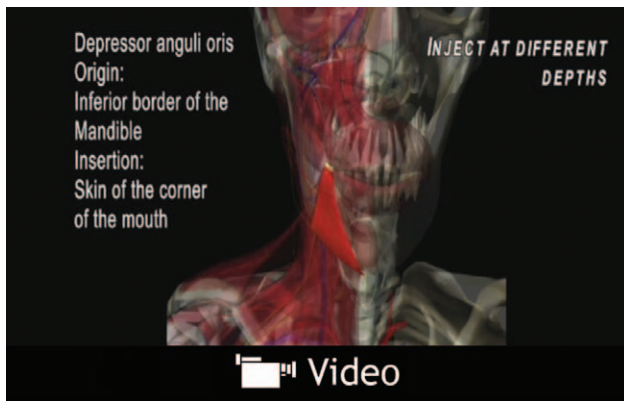
utilizing closely spaced injection sites produces a more natural outcome; (2) platysmal bands in addition to horizontal neck creases are treated by multilevel superficial injections using a microdroplet technique<sup>23</sup>; (3) the combination of a deeper injection at the muscle origin and a more superficial injection at the muscle insertion to the overlying skin delivers a more precise result; (4) finally, treatment of the masseters can slim the jawline but should be limited to patients without severe volume loss in this area. (See video, Supplemental Digital Content 2, which demonstrates lower face neurotoxin injection, available in the “Related Videos” section of the full-text article on PRSJJournal.com or, for Ovid users, at <http://links.lww.com/PRSGO/A334>.)

## SOFT-TISSUE FILLERS: HYALURONIC ACID (RESTYLANE, JUVEDERM, AND BELOTERO BALANCE)

### Scientific Background

Hyaluronic acid (HA) is a naturally occurring glycosaminoglycan that is composed of disaccharide units of glucuronic acid and N-acetyl-glycosamine linked by β-1,3 and β-1,4 bonds.<sup>24,25</sup> HA maintains skin structure and function, in part because of its water-binding capacity, which prompted its use in aesthetic injections since 2003.<sup>24,26</sup> The different formulations of HA fillers vary in their source of HA, concentration of HA, HA particle size, type of cross-linker, degree of cross-linking, and gel consistency<sup>27</sup>





**Video Graphic 1.** See video, Supplemental Digital Content 2, which demonstrates lower face neurotoxin injection, available in the “Related Videos” section of the full-text article on PRSJJournal.com or, for Ovid users, at <http://links.lww.com/PRSGO/A334>.

(Table 4). Although no evidence supports the superiority of one HA filler over another, studies clearly demonstrate increased patient satisfaction and increased duration of clinical effect during HA filler evolution.<sup>26,28</sup>

**Refinements in Clinical Application**

The authors propose that the 2 anatomic areas of the face that benefit most from technical refinements of HA injections are the periocular and perioral regions. Both sites are anatomically complex with tremendous differences in tissue quality within and between patients. Injections of the periorbital area must consider the complex interplay between the bony structures of the orbit in relation to the delicate superficial tissues and malars in a largely adynamic zone, whereas perioral injections must consider the complex interplay between the lip mucosa and thicker surrounding superficial tissues in relation to the highly dynamic perioral musculature and underlying bony structure and dentition. The most critical modification of HA injection of these sites is the blending of the product with normal saline or lidocaine and epinephrine (in a 0.02–1:1 ratio) to soften rheological properties, increase ease of injection, and decrease the risk of contour abnormalities. (See figure, Supplemental Digital Content 3, which shows panfacial volumization, <http://links.lww.com/PRSGO/A335>.)

**Periocular Rejuvenation**

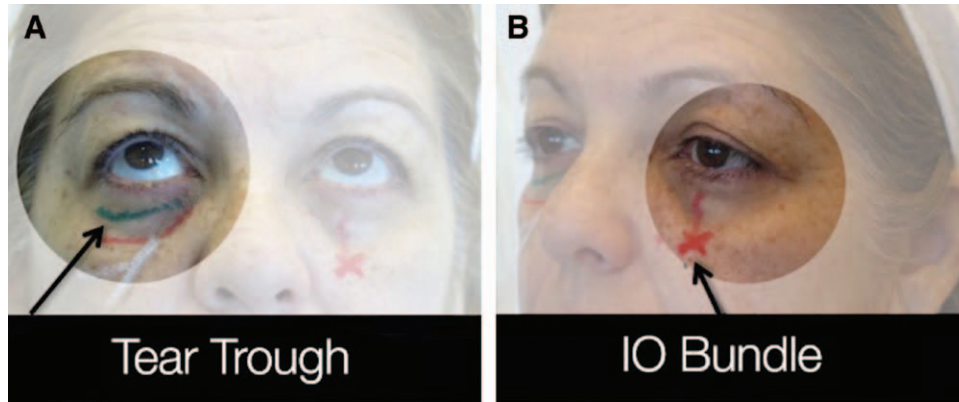
The periorbit is a highly desirable target for filler injections, as proper treatment of the area can dramatically rejuvenate the entire face.<sup>29</sup> Both the upper and lower orbits must be considered in all patients.

1. Tear trough and lower eyelid: Younger patients frequently complain about the tear trough deformity.<sup>30</sup> This presents as thin skin and orbicularis over the bony lower orbital rim. Older patients present with more complex contour deformities and loss of tissue integrity of the entire lower periorbit.
  - Patient selection: The ideal patient to treat has a clear tear trough demarcation, usually hereditary, with little lower eyelid fat and good skin and muscle tone (Fig. 1). A less ideal patient is one with fat prolapse, chronic periocular edema, poor tissue tone, and hyperpigmentation. For such a patient, surgery is a better choice. (See figure, Supplemental Digital Content 4, which shows panfacial volumization, <http://links.lww.com/PRSGO/A336>.)
  - Patient evaluation: The authors palpate the tear trough demarcation to ensure that the targeted depressed area is directly over the bony surface (Fig. 2). To simulate the predicted result to a patient, we push up the midface below the deformity to temporarily efface the tear trough demarcation. (See video, Supplemental Digital Content 5, which demonstrates assessment and injection tear trough, available in the “Related Videos” section of the full-text article on PRSJJournal.com or, for Ovid users, at <http://links.lww.com/PRSGO/A337>.) In addition, a snap test is performed to evaluate the laxity of the lower lid.
  - Product selection: The authors have used different HAs when injecting the infraorbital hollows, most commonly Belotero Balance (Merz Pharmaceuticals), Juvéderm Ultra XC (Allergan), or Restylane (Galderma). Restylane and Juvéderm Ultra XC are injected at the supraperiosteal plane to avoid the Tyndall effect and prolonged tissue edema. Alternatively, Restylane Lyft (Galderma) or Juvéderm Voluma XC (Allergan) may also be cautiously injected in the supraperiosteal plane, preferably after blending with normal saline solution and/or lidocaine and epinephrine in a 0.02 to 1:1 ratio, to modify their rheological properties. Juvéderm (Allergan) may last 1 to 3 years (Fig. 3) but has a higher incidence of edema than Restylane because

**Table 4. Formulations of HA Fillers**

Product	FDA Approval	HA Source	HA Concentration (mg/mL)	Cross-Linker	Lidocaine	Elasticity (G')	Viscosity (n*)	Depth
Galderma								
Restylane	2003	<i>S. equi</i> bacteria	20	1,4-BDDE	No	514	119,180	Superficial-medium
Restylane-L	2010	<i>S. equi</i> bacteria	20	1,4-BDDE	Yes	565	131,310	Superficial-medium
Restylane Silk	2014	<i>S. equi</i> bacteria	20	1,4-BDDE	Yes	459	107	Superficial-medium
Perlane	2010	<i>S. equi</i> bacteria	20	1,4-BDDE	No	541	127,090	Medium-deep
Perlane-L	2007	<i>S. equi</i> bacteria	20	1,4-BDDE	Yes	549	124,950	Medium-deep
Allergan								
Juvederm Ultra	2006	<i>S. equi</i> bacteria	24	1,4-BDDE	Yes	111	27,034	Superficial-medium
Juvederm Ultra Plus XC	2010	<i>S. equi</i> bacteria	24	1,4-BDDE	Yes	136	32,152	Medium-deep
Juvederm Voluma XC	2013	<i>S. equi</i> bacteria	20	1,4-BDDE	Yes	274	92,902	Medium-deep
Merz								
Belotero Balance	2011	<i>S. equi</i> bacteria	22.5	1,4-BDDE	No	30	9217	Superficial

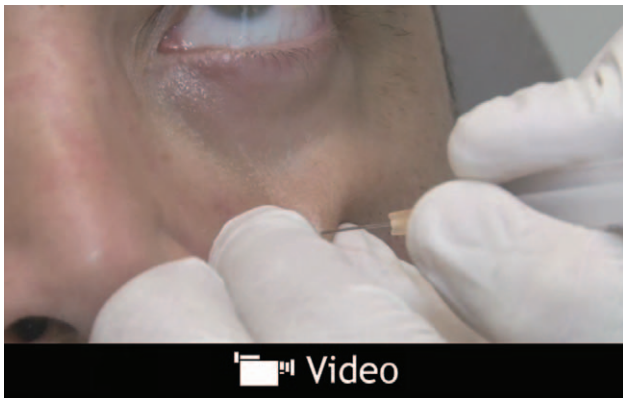BDDE, 1,4-butanediol diglycidyl ether.



**Fig. 2.** Palpate: A, Green line marks palpable infraorbital rim, and red line highlights the skin color change between eyelid and cheek. Tear trough deformity lines between green and red line. B, Infraorbital foramen marking.

of its hydrophilicity.<sup>31</sup> Belotero is a good choice and can be placed more superficially than other fillers.

- **Injection technique:** Injection safety is a major consideration for periocular rejuvenation. A clear understanding of facial anatomy is critical to avoid a catastrophic complication, such as inadvertent vessel cannulation. The principal facial foramina and large periocular vessels can be accurately localized using the patient’s pupil as a global positioning system: the supraorbital vessels are aligned with the medial iris limbus, and the infraorbital vessels fall between the pupil and the medial iris<sup>32–34</sup> (Fig. 4). The infraorbital hollows should be injected at the supraperiosteal level using needles of 29-G to 30-G or cannula of 27-G to 29-G. Needles deliver more precise implant placement, whereas cannula reduces bruising and swelling. (See video, Supplemental Digital Content 5, which demonstrates assessment and injection tear trough, available in the “Related Videos” section of the full-text article on PRSJJournal.com or, for Ovid users, at <http://links.lww.com/PRSGO/A337>.) Undercorrection is critical in this area.
2. Upper eyelid: Collapse and descent of the superior orbit occur secondary to eyelid and eyebrow (retroorbicu-



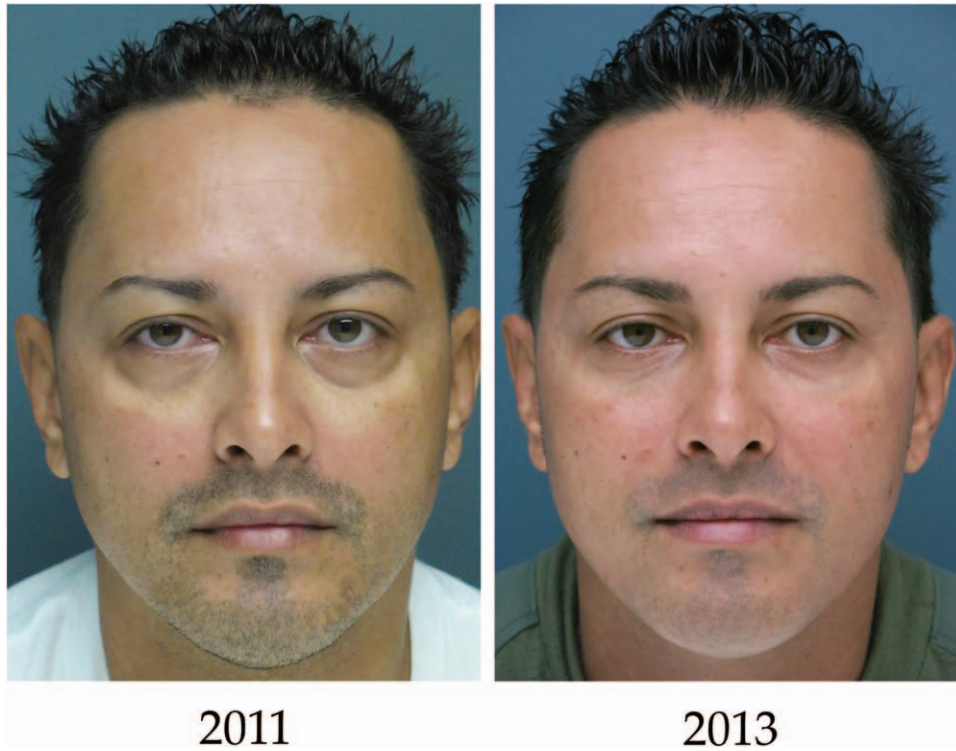**Video Graphic 2.** See video, Supplemental Digital Content 5, which demonstrates the assessment and injections to the tear trough, available in the “Related Videos” section of the full-text article on PRSJJournal.com or, for Ovid users, at <http://links.lww.com/PRSGO/A337>.

laris oculi fat [ROOF]) fat pad atrophy and bony orbital rim reabsorption. The upper lid fat pads undergo non-synchronous alterations during aging, with medial fat pad hypertrophy and central fat pad atrophy.<sup>35–37</sup>

- **Patient selection:** The ideal patient presents with a deep upper eyelid sulcus due to involutional changes or aggressive fat subtraction blepharoplasty (Fig. 5). Less commonly, a younger patient may present with a congenital deep upper eyelid sulcus or periocular fat wasting from excessive exercise or weight loss (Fig. 6). The less ideal patient is one with significant fat prolapse, dermatochalasis, brow ptosis, chronic periocular edema, and/or poor skin and muscle tone. For such a patient, surgery is a better choice.
- **Product selection:** Because upper eyelid skin is the thinnest in the body,<sup>38</sup> any injection may result in visible irregularities. Belotero Balance is a good option for this region. The authors prefer pure Belotero Balance or blended Restylane or Juvéderm Ultra XC (1 mL product mixed with 0.3 to 0.5 mL lidocaine 1% with or without epinephrine) in older, thin skin patients. In younger patients with good skin tone, the authors prefer nonblended products.
- **Injection technique:** The authors recommend cannula injection in the upper eyelid for optimal safety. The injection should be in the suborbicularis plane below the orbital rim. One must take into consideration that the supraorbital vessel is aligned with the medial iris limbus, and the supratrochlear is slightly more medial (Fig. 4). Material is placed in a retrograde manner while continuously visualizing the tip of the cannula. (See video, Supplemental Digital Content 6, which demonstrates upper eyelid, eyebrow [ROOF], and temporal fossa injection, available in the “Related Videos” section of the full-text article on PRSJJournal.com or, for Ovid users, at <http://links.lww.com/PRSGO/A338>.)

#### Perioral Rejuvenation

Perioral rejuvenation extends beyond isolated “barcode” perioral rhytid treatment, vermilion enhancement, or lip augmentation and should encompass structural enhancement of the entire perioral complex, from the alar bases to the oral commissures and marionette lines. The goal of perioral rejuvenation is to restore and improve the

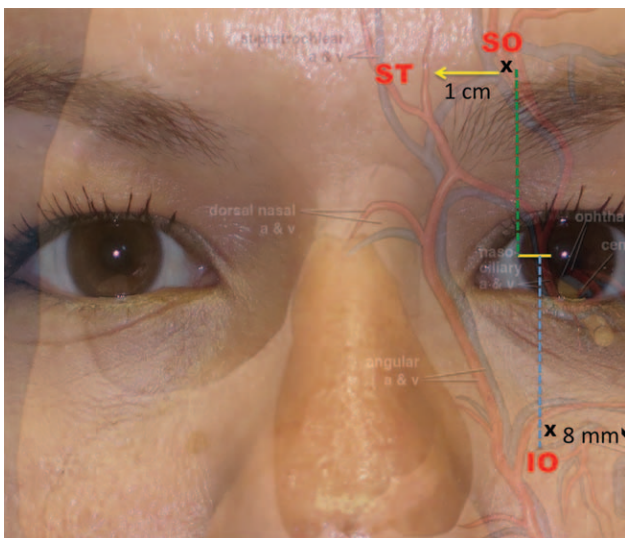


**Fig. 3.** Juvéderm’s lasting effect after 3 years of treatment, 0.50 mL per side of Juvederm Ultra XC supra-periosteal needle, retrograde injection along orbitomalar groove.

natural youthful lip contour without distorting shape and key anatomic features.

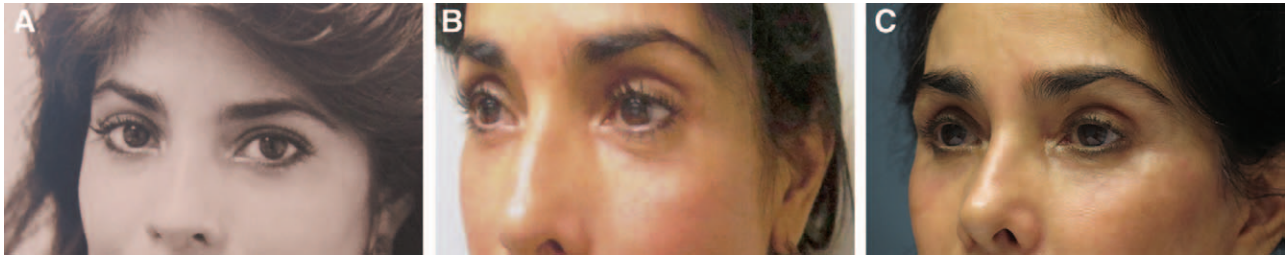- Patient selection: The ideal patient has normal occlusion without maxillary or mandibular bony absorption and presents with mild volume loss of the lip, vermilion border, and oral commissures with subtle vertical rhytids that are not fully imprinted. Patients with severe static perioral rhytids, congenital thin lips, severe perioral volume atrophy, moderate-to-severe jowling, and thick heavy faces are poor injectable candidates.

- Patient evaluation: The alar bases, nasolabial folds, vermilion border, vermilion, cutaneous lip, oral commissures, and marionette lines must be evaluated for potential volume loss and lack of definition. Severe static perioral “barcode” rhytids are notoriously difficult to treat with fillers alone and may require synergistic neuromodulation and/or skin resurfacing.
- Product selection: Currently, all HA fillers are approved for nasolabial fold treatment, but only 2 products are specifically approved for lip volumization, Juvéderm Ultra XC, and Restylane Silk (Galderma). As in other areas, the authors advocate for product selection that matches the patient’s tissue. A patient with deep, thick nasolabial folds or sunken prejowl sulci may benefit from Juvéderm Voluma XC or Restylane Lyft, whereas the application of Belotero Balance may not produce adequate correction. For the lip itself, Restylane Silk, Restylane-L (Galderma), and Belotero Balance represent the author’s preferred products that are applied without blending. Anecdotal reports exist of increased swelling with Restylane Silk. This has prompted some injectors to prescribe prophylactic oral steroids.
- Injection technique: Technique is largely dependent on practitioner experience, target region, and product selected. Both cannula and needle may be employed. Treatment of the nasolabial folds and marionettes is extensively discussed in other publications. For enhancement of the lip, product may be threaded along the wet dry junction and/or the white roll. Additional product may be placed into the lip mucosa and Cupid’s bow for final shaping. Undercorrection is

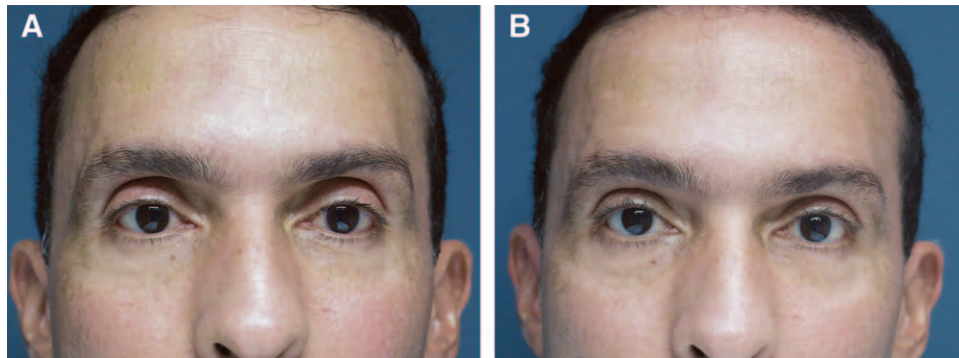


**Fig. 4.** Patient’s pupil: “GPS for safety.” IO, infraorbital; SO, supraorbital vessels; ST, supratrochlear.



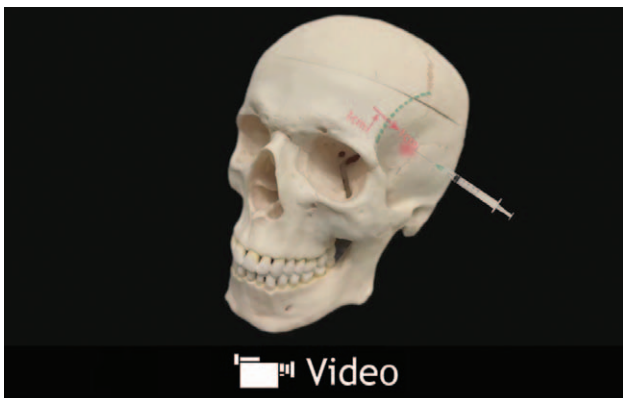


**Fig. 5.** Periocular deflation unmasked after surgery. A, 32 years old; (B) after upper and lower blepharoplasty with endobrow lifting; (C) after upper eyelid and roof filler.



**Fig. 6.** Congenital deep upper eyelid sulcus: a 49-year-old male athlete. Restylane-L 1 mL blended with 0.2 mL lidocaine 1%; 0.6 mL of blended product injected on each upper eyelid with 27 × 1 in. cannula. A, Before, (B) after.

critical and the authors recommend using less than 1 mL within the lip at each injection session. Correction of the oral commissures is required in most patients and should not be overlooked during lip volumization. For treatment of vertical “barcode” rhytids, the product is threaded at the deep dermal junction in a combination of vertical (intra-rhytid) and transverse approaches while subsiding dermal rhytid adhesions. (See figure, Supplemental Digital Content 7, which shows facial volumization to correct asymmetries <http://links.lww.com/PRSGO/A339>.)



**Video Graphic 3.** See video, Supplemental Digital Content 6, which demonstrates upper eyelid, eyebrow (ROOF), and temporal fossa injections, available in the “Related Videos” section of the full-text article on PRSJournal.com or, for Ovid users, at <http://links.lww.com/PRSGO/A338>.

## SOFT-TISSUE FILLERS: POLY-L-LACTIC ACID (SCULPTRA, GARDERMA, US)

### Scientific Background

Poly-L-lactic acid (PLLA) is not a traditional soft-tissue filler but rather a biostimulatory agent. The mechanism of action of PLLA involves the stimulation of a subclinical inflammation after which recipient site produces Type I collagen for up to 24 months after injection.<sup>39</sup> The end result includes volume restoration, increase in skin thickness, and improvement in soft-tissue texture.<sup>40</sup>

Recently, a consensus group of experts recommended the best practice guidelines for predictability in volume augmentation using PLLA with minimal adverse events.<sup>41</sup>

### Refinements in Clinical Application

The resulting major refinements in PLLA injection are summarized in Table 5.

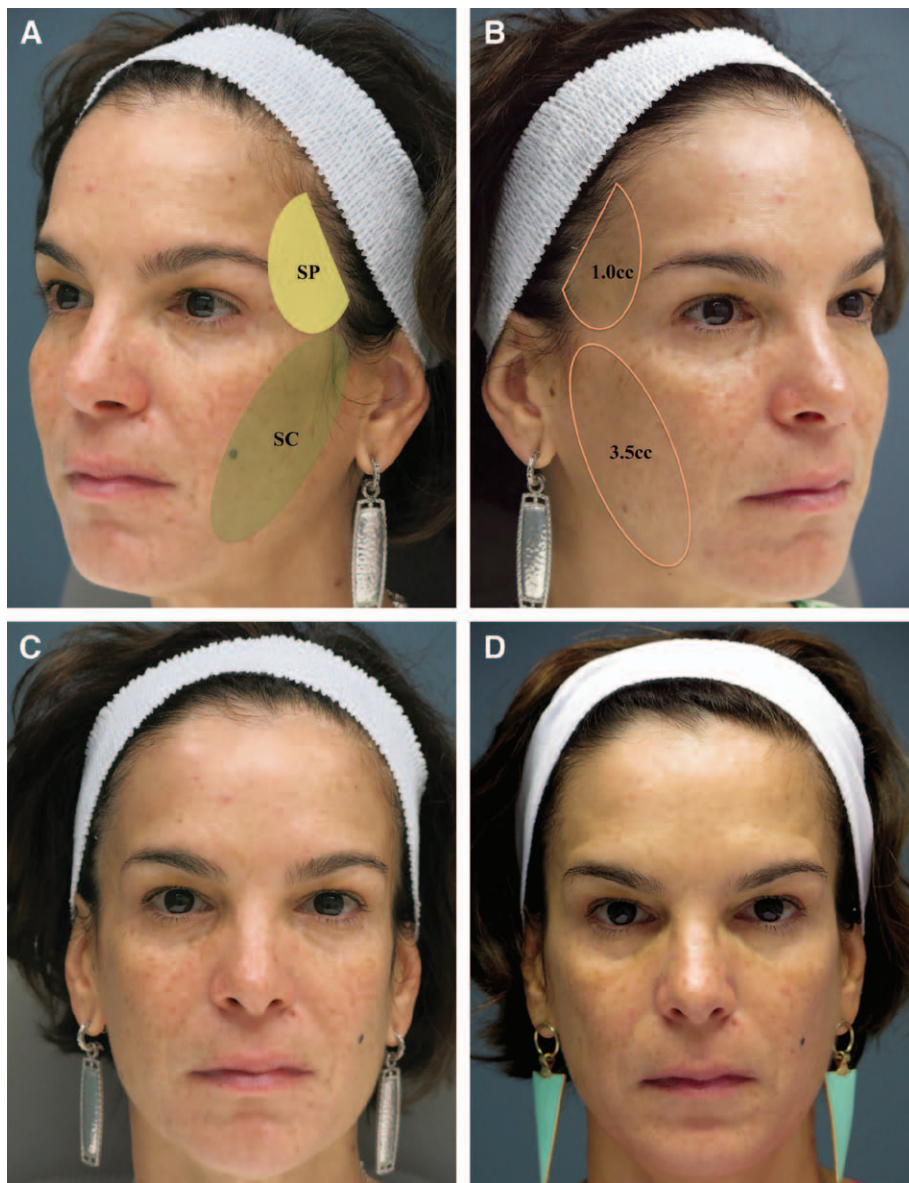#### Panfacial Restoration

**Patient Selection and Injection Technique.** Patient satisfaction after soft-tissue augmentation with PLLA has been reported to be as high as 95%<sup>42</sup>; however, patient selection is crucial to PLLA treatment success. The “ideal candidate” for PLLA injection is a young-middle-aged patient with panfacial volume loss. (See figure, Supplemental Digital Content 8, which shows the lasting effect over 2 years: 50-year-old patient Sculptra results after 3 sessions with 2 vials per session, each vial 9 mL total volume [7 mL sterile water with 2 mL lidocaine 1% with epinephrine] and 6-week treatment sessions’ interval, <http://links.lww.com/>

**Table 5. Comparison of Sculptra Consensus Recommendation and Author Preferences**

Step	Consensus Recommendation	Author Preferences
Reconstitution/dilution	Slowly add 7–8 mL sterile water for injection or bacteriostatic water	Slowly add 7 mL sterile water for injection or bacteriostatic water
Hydration	Hydrate at room temperature for $\geq 24$ h	Hydrate at room temperature for $\geq 48$ h
Final injection volume for facial treatment	9 mL, achieved by the addition of 1–2 mL lidocaine (with or without epinephrine) immediately before injection	9 mL, achieved by the addition of 2 mL lidocaine (with or without epinephrine) immediately before injection
Final injection volume for décolletage treatment	11–16 mL, achieved by further dilution with additional SWFI or bacteriostatic water and 1–2 mL lidocaine (with or without epinephrine) immediately before injection	11–16 mL, achieved by further dilution with additional SWFI or bacteriostatic water and 2 mL lidocaine (with or without epinephrine) immediately before injection
Vials per session	1–2 vials per session	1–2 vials per session*
Massage after treatment	5 d; 5 times a day; 5 min	5 d; 3 times a day; 2–3 min
Needle caliber to avoid clogging	25-G $\times$ 1 <sup>1/2</sup> -in. needle	25-G $\times$ 1-in. needle

\*In most patient, 1 vial per session.  
SWFI, sterile water for injection



**Fig. 7.** Sculptra peanut face patient: 45-year-old patient, 4.5 mL on each side, 1 vial per session. Second session 3 months after and third session a year after the first session. A, Injection depth; (B) amount injected per zone (C) before treatment; (D) 1 year after first injection session. SC, subcutaneous; SP, supraperiosteal.



*PRSGO/A340*.) Additional types of patients who are ideal candidates for PLLA treatment as per authors' experience are the following:

- a. "Peanut Face" patients—temporal–preauricular zone weakness or peripheral facial frame loss (Fig. 7)
- b. Patients with skin-texture actinic damage due to chronic sun exposure (See figure, Supplemental Digital Content 9, Sculptra skin texture: 57-year-old patient Sculptra results after 6 sessions with a total of 9 vials, each vial 9 mL total volume [7 mL sterile water with 2 mL lidocaine 1% with epinephrine]. The treatment history: 2 vials during first 3 sessions every 6 weeks, then 1 vial every year for maintenance, <http://links.lww.com/PRSGO/A341>.)
- c. Patients with congenital or traumatic facial asymmetries (See figure, Supplemental Digital Content 10, which shows Sculptra Asymmetry: Right side more deflated 45-year-old patient Sculptra results after 6 sessions with a total of 10 vials, each vial 9 mL total volume [7 mL sterile water with 2 mL lidocaine 1% with epinephrine]. The treatment history: 2 vials during first 4 sessions every 6 weeks, then 1 vial every year for maintenance, <http://links.lww.com/PRSGO/A342>.)

#### **Decollete and Buttock Rejuvenation**

Other described uses of PLLA are hand rejuvenation, chest/décolleté, and buttock<sup>43,44</sup> (Fig. 8). Variation of reconstitution depends on treatment area<sup>45–47</sup> (Table 6).

**Patient Selection and Injection Technique.** The most critical modification of PLLA injection of these sites is the hyperdilution of the product (>7 mL per vial) and extended product hydration (>1 wk).

## **SOFT-TISSUE FILLERS: CALCIUM HYDROXYLAPATITE (Radiesse, Merz, US)**

#### **Scientific Background**

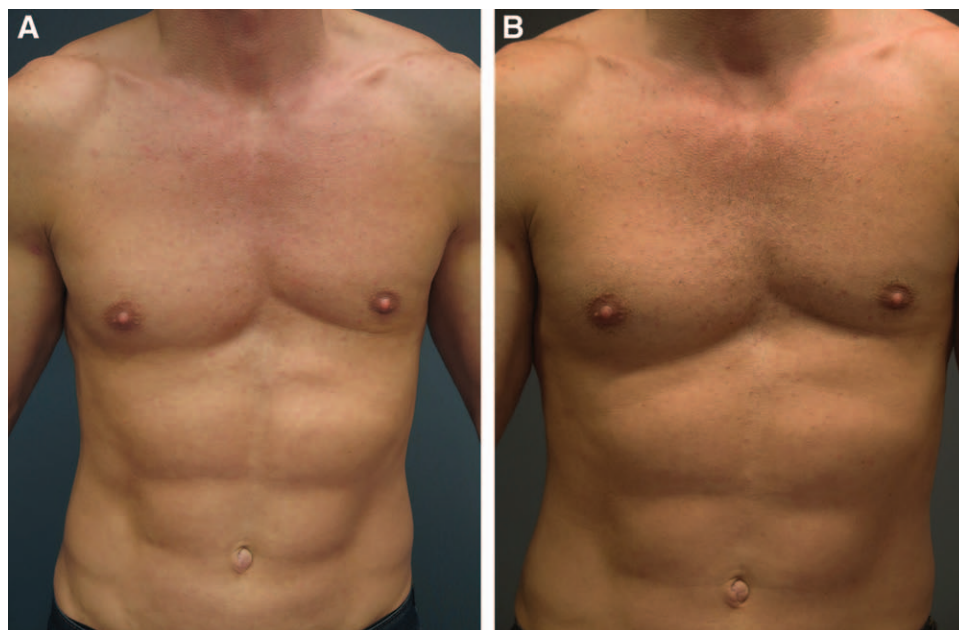
Calcium hydroxylapatite (CaHA), composed of synthetic CaHA microspheres suspended in an aqueous carboxymethylcellulose gel carrier, was introduced in 2006 as a dermal filler for facial wrinkles and folds<sup>25</sup> and was approved for hand rejuvenation in 2015.<sup>48–53</sup> Although CaHA fillers are generally well tolerated, they can produce increased injection-site reactions and granuloma formation when compared with HA fillers<sup>54,55</sup> and should be utilized by experienced injectors in the appropriate applications.<sup>56,57</sup>

#### **Refinements in Clinical Application**

The recent introduction of longer lasting HA fillers with greater lifting power in the context of residual inflammatory scarring in surgical areas previously treated with CaHA injections has led to a shift in CaHA applications. The authors' preference is to use CaHA specifically for the volumization of deep supraperiosteal regions that are not dissected during standard surgical rejuvenation of the face and for subcutaneous hand rejuvenation.

#### **Facial Volumetric Augmentation**

The ideal patient presents with discrete volume loss requiring volumetric augmentation, rather than superficial line filling. Either needles or cannulas can be used. Ideal zones for supraperiosteal injection are mental protuberance, prejowl sulcus, temporal fossa, mandibular angle, and alar bases. The most critical modification of CaHA injection of these sites is the blending of the product with normal saline or lidocaine and epinephrine (in a 0.02–1:1



**Fig. 8.** Left chest volume restoration after implant removal. Three sessions, 1 vial per session, reconstitution 7 mL sterile water, 2 mL Xilocaine 1% with epinephrine plus 2 mL Bupivacaine 0.05% (total vial volume, 11 mL). A, before first session; (B) after second session.

**Table 6. Recommended Reconstitution Volume of PLLA for Nonfacial Rejuvenation**

Area	Reconstitution Volume	Needle
Hand	9–10 mL volume (8 mL of bacteriostatic water plus 1–2 mL of lidocaine 1%) <sup>43</sup>	26-G needle <sup>43</sup>
	8–10 mL dilution per vial (6 mL SWFI + 2 mL of 1% lidocaine) <sup>44</sup>	25-G needle <sup>44</sup>
	14 mL (5 mL SWFI and 9 mL lidocaine HCl 1%) <sup>47</sup>	25-G needle or cannula <sup>47</sup>
	10 mL (9 mL of bacteriostatic sterile water plus 1 mL 1% lidocaine without epinephrine) <sup>67</sup>	25- or 27-G needle <sup>44</sup>
Chest/décolleté	10 mL of sterile water <sup>45</sup>	27-G needle <sup>45</sup>
	24 mL (5 mL SWFI and 19 mL lidocaine HCl 1%) <sup>47</sup>	27-G needle <sup>47</sup>
Buttock	12 mL (5 mL SWFI and 7 mL lidocaine 1%) <sup>47</sup>	25-G needle or cannula <sup>47</sup>

**Table 7. Recommended Formulation for Hand Treatment with Radiesse**

Author	Amount of Radiesse (mL)	Blended with	Bolus or Threads	Amount Injected	Needle or Cannula
Busso and Applebaum <sup>59</sup> Edelson <sup>58</sup>	1.3	0.1 mL lidocaine 2%	1 bolus	0.5–1.4 mL per bolus	Needle
	1.3	0.5 mL lidocaine 2%	2–4 boluses	0.2–0.5 per bolus; 1–2 (1.3 mL) syringes per hand	27- or 28-G needle
Marmur et al <sup>60</sup> Gargasz and Carbone <sup>61</sup>	0.3	0.12 mL lidocaine 2%			
	1.3	2.0 mL lidocaine 2%	3–5 boluses	0.3–1 mL per bolus	25-G needle
Nijhawan et al <sup>62</sup>	1.3	0.5 mL lidocaine before Radiesse (not diluted)	1–2 boluses	0.5–1.3	
	1.5	1.5 mL lidocaine 2%	Threads/fanning	3 mL of blended Radiesse per hand	Cannula
Fabi and Goldman <sup>63</sup>	1.5	0.3 mL lidocaine 1% + 1.2 mL bacteriostatic 0.9% NaCl	1 bolus		Needle assumed
Kühne and Imhof <sup>64</sup>	0.8	1 part lidocaine:4 Radiesse, up to 0.8 mL of anesthetic	1 bolus		28-G needle
Eviatar et al <sup>66</sup>	1.5	1 mL 2% lidocaine with epinephrine	Linear threading	0.4 mL per thread; 1 (1.5 mL) syringe per hand	
Gubanova and Starovatova <sup>65</sup>	0.8	0.2 lidocaine	Both; multiple boluses or fanning		27-G needle or 25-G cannula

ratio) to soften its rheological properties and increase ease of injection. The authors recommend microbolus injections (0.1–0.3 mL) to avoid overfilling as CaHA dissolution cannot be achieved with hyaluronidase.

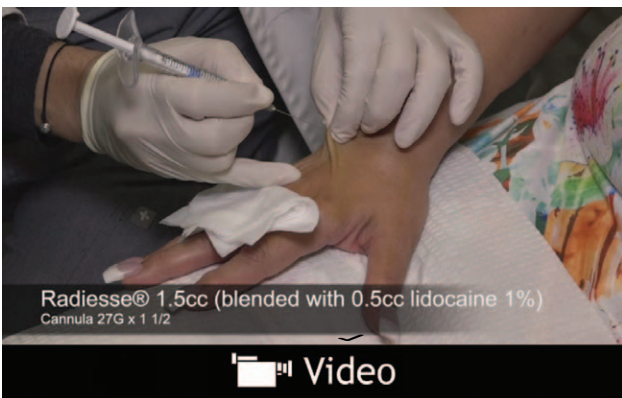**Hand Rejuvenation**

CaHA has distinct advantages over the other fillers in the hand because of its white color that provides a concealing effect over veins and tendons and its malleability.<sup>58</sup> The authors recommend the use of blended CaHA for hand

volumization with lidocaine 1% to 2%, 0.1 to 1 mL per CaHA syringe, to decrease pain and viscosity<sup>58–66</sup> (Table 7). Either needles or cannulas may be safely<sup>65</sup> utilized, with the benefit of a single entry point with cannulas. (See video, **Supplemental Digital Content 11**, which demonstrates hands Radiesse cannula injection, available in the “Related Videos” section of the full-text article on PRSJJournal.com or, for Ovid users, at <http://links.lww.com/PRSGO/A343>.) Increased adverse effects are associated with higher volumes injected.<sup>60</sup> The authors agree with the current recommendations not to exceed 3 mL of CaHA per hand<sup>60</sup> (Table 7).

**CONCLUSIONS**

The field of facial aesthetics has evolved dramatically over the past 2 decades. Our increased understanding of 3-dimensional structural volume restoration in combination with the continuous development of novel injectable products with distinct properties has stimulated this evolution. Consequently, it has become critically important to understand not just the basic technical approaches to volumization and neuromodulation but more importantly the unique nuances of patients’ tissues in relation to innate product characteristics and the potential to modify the latter to match the former. Blending or “customizing” injectable products with anesthetic agents or other diluents can often result in a better outcome for complex areas, such as the periorbital and perioral areas, hands, and décolletage.



**Video Graphic 4.** See video, Supplemental Digital Content 11, which demonstrates Radiesse cannula injection into the hands, available in the “Related Videos” section of the full-text article on PRSJJournal.com or, for Ovid users, at <http://links.lww.com/PRSGO/A343>.

**Table 8. Filler and Neurotoxins Complications**

Type	Complication	Risk	How to Prevent
Minor	Bruising or ecchymosis	Anticoagulant or any substance that may prolong bleeding time	Pull the skin taut in well-lit room before injecting. Apply an ice pack for 15 min after treatment
	Pain upon injection	Especially in apprehensive patient	Topical compounded anesthesia, ice pack, stimulate skin touch just before injection
	Mild pain after injection	E.g., temporal area or headache	May use acetaminophen
	Edema Visible material or prolonged edema	Especially periocular zone Specially on periocular zone	Avoid hydrophilic HA fillers and superficial injections Use blended products and cannulas, keep material injection below muscle (hyaluronidase 10–20 units to dissolve ≈0.1 mL of HA)
Major	Necrosis Vessel embolization	Filler injections on glabellar, nose dorsum/lateral, temporal fossa, and canine fossa	Aspiration, slow injection, use of cannula, anatomy knowledge, keep moving, small syringe, use of vasoconstrictor

In addition, recent patient-perceived outcome data suggest that product customization may be important in specific patient populations. For example, older patients may perceive more of a benefit from full neuromodulator correction, whereas men and younger women may prefer undercorrection.<sup>8</sup> Recent novel data confirming differential strain reduction patterns among the 3 neurotoxins further support customized treatments within and between patients.<sup>9</sup> The authors reviewed current FDA-approved injectables and described how, through clinical experience, product modification can produce safe and natural results with excellent patient outcomes. We provided our recommendations for subtle alterations in product profiles in discrete anatomic sites for both inexperienced and experienced injectors. The incorporation of these customized techniques will enable cosmetic practitioners to produce refined individualized results for the increasingly discerning cosmetic patient population.

Complications and adverse events with injectables can be prevented in most cases. Nevertheless, every patient is advised of these uncommon events and most accept the risk by affixing their signature to consent (Table 8).

**José Raúl Montes, MD, FACS, FACCS**

735 Ponce de León Avenue  
Auxilio Mutuo Medical Tower, Suite 813  
San Juan, Puerto Rico 00917  
E-mail: jrmonespr@aol.com

#### REFERENCES

- 2014 Plastic Surgery Statistics Report. American Society of Plastic Surgeons. Available at: <https://d2wirczt3b6wjm.cloudfront.net/News/Statistics/2014/plastic-surgerystatistics-full-report-2014.pdf>. Accessed January 8, 2016.
- Gart MS, Gutowski KA. Aesthetic uses of neuromodulators: current uses and future directions. *Plast Reconstr Surg*. 2015;136:62S–71S.
- BOTOX® Cosmetic Prescribing Information. Allergan. Available at: [http://www.allergan.com/assets/pdf/botox\\_cosmetic\\_pi.pdf](http://www.allergan.com/assets/pdf/botox_cosmetic_pi.pdf). Accessed January 19, 2016.
- Full Prescribing Information – Dysport. Galderma. Available at: <http://www.galderma.com.au/Portals/4/Pis%20and%20CMIs/April%2016%20uploads/Dysport%20Product%20information%20V2%207%20125U%20%202%20Dec%202015.pdf>. Accessed January 19, 2016.
- Prescribing Information – Xeomin. Merz Pharmaceuticals. Available at: <http://www.xeominaesthetic.com/wp-content/uploads/XEOMIN-Prescribing-Information.pdf>.
- Rappl T, Parvizi D, Friedl H, et al. Onset and duration of effect of incobotulinumtoxinA, onabotulinumtoxinA, and abobotulinumtoxinA in the treatment of glabellar frown lines: a randomized, double-blind study. *Clin Cosmet Investig Dermatol*. 2013;6:211–219.
- Kerscher M, Roll S, Becker A, et al. Comparison of the spread of three botulinum toxin type A preparations. *Arch Dermatol Res*. 2012;304:155–161.
- Wilson AJ, Chang BL, Taglienti AJ, et al. A quantitative analysis of current FDA-approved botulinum toxin formulations: a randomized double blind prospective clinical trial of comparative dynamic strain reduction. *Plast Reconstr Surg*. 2016.
- Chang BL, Wilson AJ, Taglienti AJ, et al. Patient perceived benefit in facial aesthetic procedures: FACE-Q as a tool to study botulinum toxin injection outcomes. *Aesthet Surg J*. 2016;36:810–820.
- Cliff SH, Judodihardjo H, Eltringham E. Different formulations of botulinum toxin type A have different migration characteristics: a double-blind, randomized study. *J Cosmet Dermatol*. 2008;7:50–54.
- Oliveira de Morais O, Matos Reis-Filho E, Vilela Pereira L, et al. Comparison of four botulinum neurotoxin type A preparations in the treatment of hyperdynamic forehead lines in men: a pilot study. *J Drugs Dermatol*. 2012;11:216–219.
- Cavallini M, Cirillo P, Fundarò SP, et al. Safety of botulinum toxin A in aesthetic treatments: a systematic review of clinical studies. *Dermatol Surg*. 2014;40:525–536.
- Beer KR, Boyd C, Patel RK, et al. Rapid onset of response and patient-reported outcomes after onabotulinumtoxinA treatment of moderate-to-severe glabellar lines. *J Drugs Dermatol*. 2011;10:39–44.
- Schlessinger J, Monheit G, Kane MA, et al. Time to onset of response of abobotulinumtoxinA in the treatment of glabellar lines: a subset analysis of phase 3 clinical trials of a new botulinum toxin type A. *Dermatol Surg*. 2011;37:1434–1442.
- Prager W, Bee EK, Havermann I, et al. Onset, longevity, and patient satisfaction with incobotulinumtoxinA for the treatment of glabellar frown lines: a single-arm, prospective clinical study. *Clin Interv Aging*. 2013;8:449–456.
- Nestor MS, Ablon GR. Comparing the clinical attributes of abobotulinumtoxinA and onabotulinumtoxinA utilizing a novel contralateral Frontalis model and the Frontalis Activity Measurement Standard. *J Drugs Dermatol*. 2011;10:1148–1157.
- Ascher B, Zakine B, Kestemont P, et al. A multicenter, randomized, double-blind, placebo-controlled study of efficacy and safety of 3 doses of botulinum toxin A in the treatment of glabellar lines. *J Am Acad Dermatol*. 2004;51:223–233.
- Brandt F, Swanson N, Baumann L, et al. Randomized, placebo-controlled study of a new botulinum toxin type A for treatment of glabellar lines: efficacy and safety. *Dermatol Surg*. 2009;35:1893–1901.
- Monheit G, Carruthers A, Brandt F, et al. A randomized, double-blind, placebo-controlled study of botulinum toxin type A for



- the treatment of glabellar lines: determination of optimal dose. *Dermatol Surg*. 2007;33:S51–S59.
20. Rubin MG, Dover J, Glogau RG, et al. The efficacy and safety of a new U.S. Botulinum toxin type A in the retreatment of glabellar lines following open-label treatment. *J Drugs Dermatol*. 2009;8:439–444.
  21. Baumann L, Brandt FS, Kane MA, et al. An analysis of efficacy data from four phase III studies of botulinum neurotoxin type A-ABO for the treatment of glabellar lines. *Aesthet Surg J*. 2009;29:S57–S65.
  22. Yu KC, Nettar KD, Bapna S, et al. Split-face double-blind study comparing the onset of action of onabotulinumtoxinA and abobotulinumtoxinA. *Arch Facial Plast Surg*. 2012;14:198–204.
  23. Wu W. Skin resurfacing with Microbotox and the treatment of keloids. *Botulinum Toxins in Clinical Aesthetic Practice Series in Cosmetic and Laser Therapy*. Boca Raton, FL: CRC Press;2013:190–205.
  24. Beasley KL, Weiss MA, Weiss RA. Hyaluronic acid fillers: a comprehensive review. *Facial Plast Surg*. 2009;25:86–94.
  25. Kontis TC. Contemporary review of injectable facial fillers. *JAMA Facial Plast Surg*. 2013;15:58–64.
  26. Narins RS, Brandt F, Leyden J, et al. A randomized, double-blind, multicenter comparison of the efficacy and tolerability of Restylane versus Zyplast for the correction of nasolabial folds. *Dermatol Surg*. 2003;29:588–595.
  27. Gold MH. Use of hyaluronic acid fillers for the treatment of the aging face. *Clin Interv Aging*. 2007;2:369–376.
  28. Baumann LS, Shamban AT, Lupo MP, et al; JUVEDERM vs. ZYPLAST Nasolabial Fold Study Group. Comparison of smooth-gel hyaluronic acid dermal fillers with cross-linked bovine collagen: a multicenter, double-masked, randomized, within-subject study. *Dermatol Surg*. 2007;33:S128–S135.
  29. Nguyen HT, Isaacowitz DM, Rubin PA. Age- and fatigue-related markers of human faces: an eye-tracking study. *Ophthalmology*. 2009;116:355–360.
  30. Wong CH, Hsieh MK, Mendelson B. The tear trough ligament: anatomical basis for the tear trough deformity. *Plast Reconstr Surg*. 2012;129:1392–1402.
  31. Kurkjian TJ, Ahmad J, Rohrich RJ. Soft-tissue fillers in rhinoplasty. *Plast Reconstr Surg*. 2014;133:121e–126e.
  32. Aziz SR, Marchena JM, Puran A. Anatomic characteristics of the infraorbital foramen: a cadaver study. *J Oral Maxillofac Surg*. 2000;58:992–996.
  33. Gupta T. Localization of important facial foramina encountered in maxillo-facial surgery. *Clin Anat*. 2008;21:633–640.
  34. Hwang SH, Kim SW, Park CS, et al. Morphometric analysis of the infraorbital groove, canal, and foramen on three-dimensional reconstruction of computed tomography scans. *Surg Radiol Anat*. 2013;35:565–571.
  35. Oh SR, Chokthaweesak W, Annunziata CC, et al. Analysis of eyelid fat pad changes with aging. *Ophthal Plast Reconstr Surg*. 2011;27:348–351.
  36. Rohrich RJ, Pessa JE. The fat compartments of the face: anatomy and clinical implications for cosmetic surgery. *Plast Reconstr Surg*. 2007;119:2219–2227; discussion 2228.
  37. Shaw RB Jr, Kahn DM. Aging of the midface bony elements: a three-dimensional computed tomographic study. *Plast Reconstr Surg*. 2007;119:675–681; discussion 682.
  38. Nerad J. Clinical anatomy-28. In: *Techniques in Ophthalmic Plastic Surgery: A Personal Tutorial*. Philadelphia: Saunders Elsevier; 2010.
  39. Vleggaar D. Facial volumetric correction with injectable poly-L-lactic acid. *Dermatol Surg*. 2005;31:1511–1517.
  40. Valantin MA, Aubron-Olivier C, Ghosn J, et al. Poly lactic acid implants (New-Fill) to correct facial lipoatrophy in HIV-infected patients: results of the open-label study VEGA. *AIDS* 2003;17:2471–2477.
  41. Vleggaar D, Fitzgerald R, Lorenc ZP. The history behind the use of injectable poly-L-lactic acid for facial and nonfacial volumization: the positive impact of evolving methodology. *J Drugs Dermatol*. 2014;13:s32–s34.
  42. Palm MD, Woodhall KE, Butterwick KJ, et al. Cosmetic use of poly-L-lactic acid: a retrospective study of 130 patients. *Dermatol Surg*. 2010;36:161–170.
  43. Rendon MI, Cardona LM, Pinzon-Plazas M. Treatment of the aged hand with injectable poly-L-lactic acid. *J Cosmet Laser Ther*. 2010;12:284–287.
  44. Sadick NS, Anderson D, Werschler WP. Addressing volume loss in hand rejuvenation: a report of clinical experience. *J Cosmet Laser Ther*. 2008;10:237–241.
  45. Mazzucco R, Hexsel D. Poly-L-lactic acid for neck and chest rejuvenation. *Dermatol Surg*. 2009;35:1228–1237.
  46. Schulman MR, Lipper J, Skolnik RA. Correction of chest wall deformity after implant-based breast reconstruction using poly-L-lactic acid (Sculptra). *Breast J*. 2008;14:92–96.
  47. Lorenc ZP. Techniques for the optimization of facial and nonfacial volumization with injectable poly-L-lactic acid. *Aesthetic Plast Surg*. 2012;36:1222–1229.
  48. Radiesse®. *Injectable Implant: Instructions for Use*. Franksville, WI: BioForm Medical, Inc; 2008;137:1424–1433.
  49. Marmur ES, Phelps R, Goldberg DJ. Clinical, histologic and electron microscopic findings after injection of a calcium hydroxylapatite filler. *J Cosmet Laser Ther*. 2004;6:223–226.
  50. Graivier MH, Bass LS, Busso M, et al. Calcium hydroxylapatite (Radiesse) for correction of the mid- and lower face: consensus recommendations. *Plast Reconstr Surg*. 2007;120:55S–66S.
  51. Food and Drug Administration. Radiesse® Injectable Implant - P050052/S049. June 4, 2015. Available at: [http://www.accessdata.fda.gov/cdrh\\_docs/pdf5/P050052S049a.pdf](http://www.accessdata.fda.gov/cdrh_docs/pdf5/P050052S049a.pdf). Retrieved January 25, 2016.
  52. Franksville. Radiesse® Injectable Implant: Instructions For Use For The Dorsum Of The Hand. June 2015. Available at: <http://www.radiesse.com/wp-content/uploads/Radiesse-Hands-Instructions-for-Use.pdf>. Retrieved January 25, 2016.
  53. Carruthers A, Carruthers J, Hardas B, et al. A validated hand grading scale. *Dermatol Surg*. 2008;34:S179–S183.
  54. Sadick NS, Katz BE, Roy D. A multicenter, 47-month study of safety and efficacy of calcium hydroxylapatite for soft tissue augmentation of nasolabial folds and other areas of the face. *Dermatol Surg*. 2007;33:S122–S126.
  55. Bass LS, Smith S, Busso M, et al. Calcium hydroxylapatite (Radiesse) for treatment of nasolabial folds: long-term safety and efficacy results. *Aesthet Surg J*. 2010;30:235–238.
  56. Smith S, Busso M, McClaren M, et al. A randomized, bilateral, prospective comparison of calcium hydroxylapatite microspheres versus human-based collagen for the correction of nasolabial folds. *Dermatol Surg*. 2007;33:S112–S121.
  57. Moers-Carpi MM, Tufet JO. Calcium hydroxylapatite versus nonanimal stabilized hyaluronic acid for the correction of nasolabial folds: a 12-month, multicenter, prospective, randomized, controlled, split-face trial. *Dermatol Surg*. 2008;34:210–215.
  58. Edelson KL. Hand recontouring with calcium hydroxylapatite. *Cosmet Dermatol*. 2009;8:473–479.
  59. Busso M, Applebaum D. Hand augmentation with Radiesse (calcium hydroxylapatite). *Dermatol Ther*. 2007;20:385–387.
  60. Marmur ES, Al Quran H, De Sa Earp AP, et al. A five-patient satisfaction pilot study of calcium hydroxylapatite injection for treatment of aging hands. *Dermatol Surg*. 2009;35:1978–1984.
  61. Gargas SS, Carbone MC. Hand rejuvenation using Radiesse. *Plast Reconstr Surg*. 2010;125:259e–260e.
  62. Nijhawan R, Rossi A, Perez M. Soft tissue augmentation, part 2: hand rejuvenation. *Cosmet Dermatol*. 2012;25:351–355.
  63. Fabi SG, Goldman MP. Hand rejuvenation: a review and our experience. *Dermatol Surg*. 2012;38:1112–1127.

64. Kühne U, Imhof M. Treatment of the ageing hand with dermal fillers. *J Cutan Aesthet Surg*. 2012;5:163–169.
65. Gubanova EI, Starovatova PA. A prospective, comparative, evaluator-blind clinical study investigating efficacy and safety of two injection techniques with Radiesse(®) for the correction of skin changes in aging hands. *J Cutan Aesthet Surg*. 2015;8:147–152.
66. Eviatar J, Lo C, Kirsztrot J. Radiesse. *Plast Reconstr Surg*. 2015;136:164–170.